

**ADVANCED SUBSIDIARY GCE
HUMAN BIOLOGY**

Case Studies

INSERT

WEDNESDAY 10 JANUARY 2007

2858/01

Morning

Time: 45 minutes



INSTRUCTIONS TO CANDIDATES

- Questions 1 and 2 are based on the articles which follow on pages 3 to 7 of this insert.

This insert consists of **7** printed pages and **1** blank page.

Case Study 1

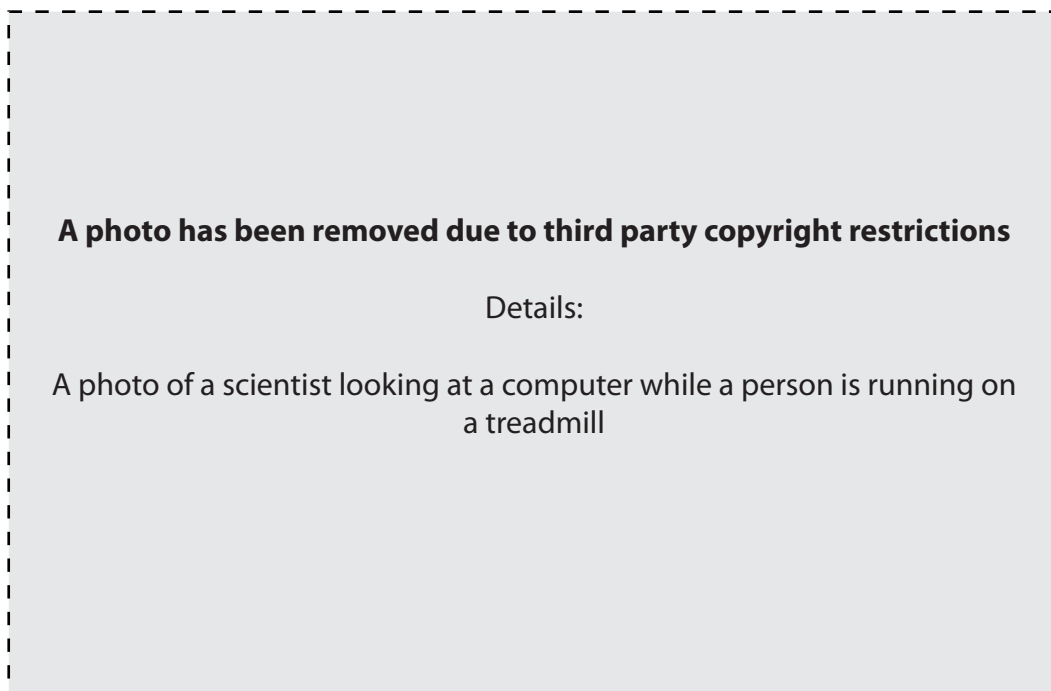TESTING THE HEART

There are a wide range of testing procedures that can be carried out either if damage to the heart is suspected or as part of a health screening programme. Some tests are designed to measure heart function directly, while others look for indicators that the heart may be at risk or that damage to the heart muscle has already occurred.

An electrocardiogram (ECG) may be used to aid in the diagnosis of heart disease or as part of a routine health screen. ECG testing does not always reveal a problem as even patients with heart disease can display a normal ECG trace. Therefore, two modifications of the ECG procedure are now routinely used.

One modification involves 24 hour 'ambulatory' monitoring of the ECG. The heart monitor is worn by the patient and takes readings approximately every 20 minutes. The data are stored. Patients are encouraged to keep a 'diary' of how they are feeling and in this way, feelings of breathlessness and discomfort can be linked to changes in the ECG trace. A fit individual who was reporting feeling 'odd' and breathless was monitored and it was found that his heart was stopping intermittently for periods of up to 20 seconds. Following the fitting of a pacemaker, no further problems were reported.

A further modification of the ECG is the exercise tolerance test or stress test. In this test, the ECG electrodes are fitted to the patient. The patient walks on a treadmill which is initially set at a slight incline and at a low pace. The patient often 'feels' that they should be going faster as their heart rate can be quite high due to adrenaline. The treadmill incline and the speed are then gradually increased so the heart rate rises. Fig. 1.1 shows a patient taking part in a stress test.



© R. Maisonneuve, Publiphoto Diffusion / Science Photo Library

Fig. 1.1

It is essential that guidelines for administering the stress test are followed and that qualified staff are on hand. It is not unknown for a patient to have a cardiac arrest following the stress test and it is essential that qualified staff are available to deal with the situation.

The ECG trace, illustrated in Fig. 1.2, is examined following the stress test. One indicator examined is the ST interval. In a normal trace, T_1 , the ST interval is horizontal or electrically neutral. Where damage has occurred in the cardiac muscle then 'ST elevation' can be observed, as shown by trace T_2 .

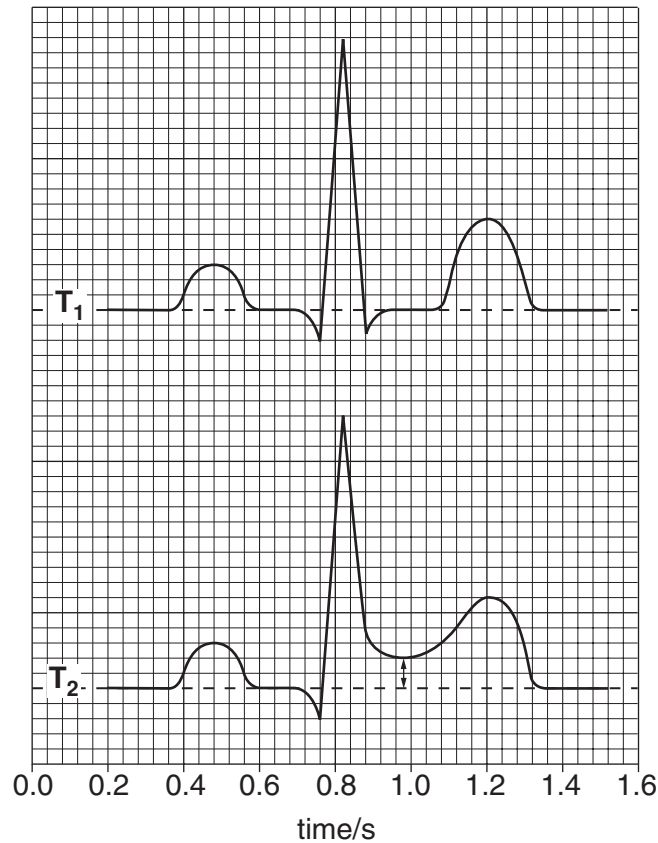


Fig. 1.2

The patient from whom trace T_2 was taken and the ST elevation was observed underwent an angiogram. There was indeed a partial blockage in one of the major coronary arteries. The patient was immediately treated with streptokinase and later underwent angioplasty.

Various blood tests can also be carried out particularly after periods of prolonged chest pain. These can include measurement of blood cholesterol concentrations where several results are obtained.

A normal cholesterol result is $3.9 - 6.6 \text{ mmol dm}^{-3}$ (dm^{-3} can also be expressed as l^{-1}). Recommended target cholesterol concentrations for an individual with coronary heart disease are:

- total cholesterol – less than 5 mmol dm^{-3}
- LDL cholesterol – less than 3 mmol dm^{-3}
- HDL cholesterol – more than 1 mmol dm^{-3}
- triglycerides – less than 2 mmol dm^{-3} .

Tests are also carried out for two 'cardiac enzymes'. One of the enzymes measured is creatine kinase (CK) which is found in the cells of the heart. The presence of CK in the blood can indicate cardiac muscle injury. CK blood concentration rises and peaks during the first day following myocardial injury, and then falls to normal after the second day.

Lactic dehydrogenase (LDH) is another enzyme that is released by the cells of the heart in response to damage. Raised LDH concentrations do not appear until 12-48 hours after a myocardial infarction and reach a peak after 48-72 hours. It then takes seven days to return to normal. However, LDH is also released from other areas of the body and therefore can lead to a false positive result when used in isolation.

If a patient reports chest pains, the concentrations of CK and LDH, in combination with other tests such as the ECG and an angiogram, can confirm diagnosis of coronary heart disease. An angiogram is a method for locating damage within the coronary arteries. Various treatments may then be given, but streptokinase is given only once, due to the potential for a dangerous immune response.

Case Study 2

SLAPPED CHEEK

Lisa, a primary school teacher, is 28 weeks pregnant. There is an outbreak of a viral infection called 'slapped cheek' at the school where she teaches. The children who have been diagnosed with the virus have a slightly raised temperature and a red rash on their cheeks but otherwise seem perfectly healthy. However, Lisa is concerned that she may have been infected by the virus. She has made an appointment with her midwife to discuss the situation.

Lisa: *I haven't even heard of slapped cheek before, so what exactly is it?*

Midwife: It's sometimes called 'fifth disease' since it was the fifth red rash type disease to be identified. You will certainly have heard of the others and at least one of them – rubella – you will already have been checked for.

Lisa: *That's right. I was checked before I was even pregnant. This isn't the same virus is it?*

Midwife: No, definitely not. Rubella is in a class of its own. I see from your notes that you have the antibodies to rubella so that is not a problem.

Lisa: *Thank goodness.*

Midwife: But slapped cheek is a very different virus. You've heard of DNA? (*Lisa nods*) Slapped cheek virus does have DNA but, unlike your DNA, it is single stranded. We need to take a blood sample today and see what your immune status is like for slapped cheek. What we may not be able to tell is if you have been exposed to this virus during your pregnancy or some time before.

Lisa: *Can you just tell me what might happen? I really am very worried.*

Midwife: Well, I'll be frank with you. There can be a problem if you pick up the virus early in pregnancy when it does slightly increase the risk of miscarriage. But can I try and reassure you? We are talking about less than 10% of women who get infected in early pregnancy having problems and if you were infected before you became pregnant, then the risks are much smaller. At least 50% of women are immune from childhood exposure. Of course you might not have antibodies at all, in which case you have not yet been infected – infections this late in pregnancy are much less likely to affect the baby.

Lisa: *But why? Why might it cause problems?*

Midwife: Well it helps if you realise that the virus reproduces in the bone marrow reticulocytes – you probably know them as stem cells. (*Lisa nods*) The virus DNA takes over from the DNA of the stem cells – it sort of substitutes its own DNA. This causes a temporary shut down in red cell production. For the children in your class this may cause a small drop in haemoglobin concentration. If the child has a hereditary red cell disorder, a crisis may occur with severe anaemia. This is caused by the destruction of red cells and the failure to produce new ones. This is pretty much what may happen if the virus crosses into a foetus, where it may cause a condition called foetal hydrops. Foetal hydrops can also be caused by rhesus incompatibility – this is another blood test that you have had.

Lisa: *How will I know if my baby is at risk?*

Midwife: Try not to worry. As you have made it to 28 weeks, it is unlikely that your baby has been affected. Diagnosis is made by ultrasound and when you had your last one done at 20 weeks everything was fine. However, we can arrange for a further scan to see if everything is OK. We will monitor you carefully for the remaining weeks. We can also check the cord blood for antibodies to this virus after delivery to see if the virus crossed the placenta. I know you are worried, but we really will keep a close eye on you and remember, in the vast majority of cases of this virus during pregnancy, both mother and baby are fine.

Lisa: *Well I won't pretend I'm not worried but thank you for explaining. I have arranged to have some time off so I can come in for the scan any time. I'll get the appointment sorted on my way out. Thanks again.*

Copyright Acknowledgements:

Fig. 1.1 © R. Maisonneuve, Publiphoto Diffusion / Science Photo Library.

Permission to reproduce items where third-party owned material protected by copyright is included has been sought and cleared where possible. Every reasonable effort has been made by the publisher (OCR) to trace copyright holders, but if any items requiring clearance have unwittingly been included, the publisher will be pleased to make amends at the earliest possible opportunity.

OCR is part of the Cambridge Assessment Group. Cambridge Assessment is the brand name of University of Cambridge Local Examinations Syndicate (UCLES), which is itself a department of the University of Cambridge.